

# COVID-19 in a Newborn Caught on Magnetic Resonance Imaging: A Case Report

KRISHNA KIRAN SOMASHEKAR KARANTH<sup>1</sup>, BK PRAVEEN<sup>2</sup>, AYSHA N ABNA<sup>3</sup>

## ABSTRACT

The Coronavirus Disease 2019 (COVID-19) remains a global public health threat. It is generally believed that children, especially neonates, are relatively spared from the disastrous effects of COVID-19 compared to adults. Most symptomatic children experience only mild respiratory and gastrointestinal symptoms. Central Nervous System (CNS) complications in COVID-19 are unusual in children and neonates. In this report, the authors present the case of a five-day-old COVID-19 positive neonate who presented with convulsions and tachypnoea. Magnetic Resonance Imaging (MRI) findings suggested a cytotoxic oedematous pattern. This child made a complete recovery after receiving appropriate management. There is limited data available regarding COVID-19 in neonates, and only a few similar cases of neonatal involvement have been described in the literature. The aim of this report is to highlight the unusual imaging manifestations of COVID-19 in a neonate.

**Keywords:** Coronavirus disease-2019, Encephalopathy, Magnetic resonance imaging, Neonate

## CASE REPORT

A five-day-old newborn presented to our hospital with convulsions and difficulty breathing. The neonate was delivered in an outside hospital by Lower Segment Caesarean Section (LSCS) due to foetal distress and had a birth weight of 2600 gm with an APGAR score of 9/10 and 9/10 at one and five minutes, respectively. Convulsions and tachypnoea started on the 5<sup>th</sup> day of life. The convulsions were in the form of jerky movements of the upper limbs, with each episode lasting about five seconds. There was no significant antenatal history.

The child required multiple anticonvulsants and mechanical ventilation. During investigations, an oropharyngeal swab for Severe Acute Respiratory Syndrome (SARS) Coronavirus (CoV) RNA Real Time Reverse Transcriptase-Polymerase Chain Reaction (RT-PCR) test was positive. A brain MRI was performed on the 8<sup>th</sup> day of admission. The MRI findings revealed diffusion restriction in the corpus callosum, periventricular region, and Fluid Attenuation Inversion Recovery (FLAIR) sequence hyperintensities in bilateral white matter [Table/Fig-1]. Cerebro-spinal Fluid (CSF) analysis by lumbar puncture was

normal. The chest radiograph was normal. CT of the thorax was not performed as it is not recommended when the chest radiograph is normal.

Both parents had a dry cough but tested negative for COVID-19. The child improved with mechanical ventilation and anticonvulsants and was discharged on the 20<sup>th</sup> day of life with stable vitals. At three months of age, the infant had achieved age-appropriate milestones.

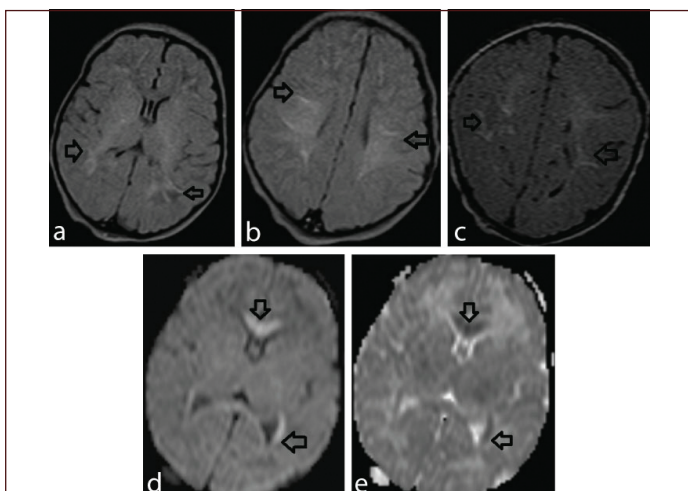
## DISCUSSION

There is limited data on COVID-19 in neonates. A population-based study conducted in the UK during the first wave of the pandemic reported 66 confirmed cases of SARS-CoV-2 infection in newborns, resulting in an incidence rate of 5.6 per 10,000 live births [1]. Most infected neonates present with respiratory symptoms (57.47%), while neurological symptoms were observed in 26.6% of cases [2].

In this particular case, the neonate exhibited respiratory symptoms and tested positive for SARS-Cov-2 through RT-PCR during the COVID-19 pandemic in India. The exact source of infection is unknown as both parents tested negative. This finding aligns with Trevisanuto D et al., who conducted a systematic review of published articles on neonatal COVID-19 and found that the source of infection remains unclear, as only 50% of cases had contact with an infected mother [3]. It was also postulated that the source of infection could be contact with different infected individuals, such as family members or healthcare providers [3].

The cellular and molecular mechanisms underlying SARS-Cov-2 neurological outcomes in neonates are not well understood. The olfactory epithelium, specifically the ACE2 receptor, is considered a potential entry point for the virus [2]. Once inside the cell, the virus triggers a robust immune response, leading to cytokine release [2].

Various forms of COVID-19 encephalopathy have been described in the literature. Lindan CE et al., studied 38 cases of children (aged 0-18 years) with COVID-19 encephalopathy [4]. The most common MRI findings in their series were consistent with Acute Disseminated Encephalomyelitis (ADEM), characterised by lesions in white matter,



**[Table/Fig-1]:** Axial (a,b) and coronal (c) FLAIR images reveal hyperintensity in periventricular, subcortical white matter bilaterally (marked by arrows). Diffusion (d) and ADC (e) reveal diffusion restriction in genu, splenium of corpus callosum and periventricular white matter.

gray matter, and the corpus callosum. Other patterns included co-infections of the Central Nervous System (CNS) such as tuberculosis, stroke, and cerebral haemorrhage, as well as incidental splenic lesions and myositis of the neck and face. The pattern observed in this case aligns with ADEM type [4].

Manara O et al., described MRI brain findings involving six neonates who had a fever and feeding difficulty with a positive swab test for COVID-19 [5]. Abnormalities were noted only on diffusion images in the corpus callosum in five of the six neonates. They called it Cytotoxic Lesions of the Corpus Callosum (CLOOC) and attributed it to demyelination or viral encephalitis. Martin PJ et al., described a COVID-19 positive neonate in whom MRI showed lesions with diffusion restriction in the corpus callosum, periventricular, and deep white matter [6].

Another similar case was reported by Fragoso DC et al., [7]. Their case showed a COVID-19 positive neonate whose MRI brain showed corpus callosum and deep white matter diffusion-restricting lesions. They also hypothesised that these abnormalities reflected infection with an immune response and treated neonates with high-dose steroids.

Alves L et al., have reported a three-day-old COVID-19 positive neonate with afebrile seizures, and MRI demonstrating bilateral periventricular and corpus callosal lesions [8]. They also believed an intense inflammatory response was responsible for the imaging findings.

It can be said that of the few cases in the literature of COVID-19 positive newborns with neurological manifestations, a common finding in imaging is that of lesions in the corpus callosum and deep white matter, particularly noted on diffusion images [5-8]. These abnormalities most likely represent immune responses following SARS-CoV-2 infection.

This case has certain limitations; the exact mode of transmission is not known. Follow-up of the neonate is needed to look for long-term

complications. This is the first reported case of a COVID-19 neonate with positive MRI brain findings from India.

## CONCLUSION(S)

The COVID-19 encephalitis is rare in neonates. The presence of white matter lesions with restricted diffusion sequence in the MRI brain of a COVID-19 positive neonate indicates CNS involvement and is most likely immune-mediated. COVID-19 encephalitis can manifest in various ways in neonates. Neonatologists, paediatric neurologists, and radiologists should be aware of the clinical and imaging findings.

## REFERENCES

- [1] Ryan L, Plötz FB, van den Hoogen A, Latour JM, Degtyareva M, Keuning M, et al. Neonates and COVID-19: State of the art. *Pediatric Research*. 2021;91:432-39.
- [2] de Moraes FM, de Souza JW, Alves LP, de Siqueira MF, dos Santos AP, de Carvalho Berardo MM, et al. SARS-COV-2 infection and possible neonatal neurological outcomes: A literature review. *Viruses*. 2022;14(5):1037.
- [3] Trevisanuto D, Cavallin F, Cavicchiolo ME, Borellini M, Calgaro S, Baraldi E. Coronavirus infection in neonates: A systematic review. *Arch Dis Child Fetal Neonatal Ed*. 2021;106(3):330-35.
- [4] Lindan CE, Mankad K, Ram D, Kocielek LK, Silvera VM, Boddaert N, et al. Neuroimaging manifestations in children with SARS-COV-2 infection: A multinational, Multicentre Collaborative Study. *The Lancet Child & Adolescent Health*. 2021;5(3):167-77.
- [5] Manara O, Barletta A, Pezzetti G, Gerevini S. Brain imaging findings in COVID-19 positive newborns. *Neuroimaging of Covid-19 First Insights based on Clinical Cases*. 2021:83-86.
- [6] Martin PJ, Felker M, Radhakrishnan R. MR imaging findings in a neonate with Covid-19-associated encephalitis. *Pediatric Neurology*. 2021;119:48-49.
- [7] Fragoso DC, Marx C, Dutra BG, da Silva CJ, da Silva PM, Martins Maia Junior AC, et al. Covid-19 as a cause of acute neonatal encephalitis and cerebral cytotoxic edema. *Pediatr Infect Dis J*. 2021;40(7):e270-71.
- [8] Alves L, Alcântara T, Hazin A, Lucato L, Ferraz de Magalhães JJ, Alves J, et al. Cerebral white matter injury in a newborn infant with COVID-19. *Neurol Clin Pract*. 2022;12(3):e22-e24.

### PARTICULARS OF CONTRIBUTORS:

1. Radiologist, Department of Radiodiagnosis, Father Muller Medical College, Mangalore, Karnataka, India.
2. Paediatrician and Neonatologist, Department of Paediatrics, Father Muller Medical College, Mangalore, Karnataka, India.
3. Postgraduate Student, Department of Radiodiagnosis, Father Muller Medical College, Mangalore, Karnataka, India.

### NAME, ADDRESS, E-MAIL ID OF THE CORRESPONDING AUTHOR:

Dr. Krishna Kiran Somashekar Karanth,  
Radiologist, Department of Radiodiagnosis, Father Muller Medical College,  
Mangalore-575002, Karnataka, India.  
E-mail: drkrishnakiran@gmail.com

### AUTHOR DECLARATION:

- Financial or Other Competing Interests: None
- Was informed consent obtained from the subjects involved in the study? NA
- For any images presented appropriate consent has been obtained from the subjects. NA

### PLAGIARISM CHECKING METHODS: [Jain H et al.]

- Plagiarism X-checker: Sep 05, 2022
- Manual Googling: May 29, 2023
- iThenticate Software: May 31, 2023 (7%)

### ETYMOLOGY: Author Origin

EMENDATIONS: 7

Date of Submission: **Aug 21, 2022**

Date of Peer Review: **Sep 15, 2022**

Date of Acceptance: **Jun 01, 2023**

Date of Publishing: **Dec 31, 2023**